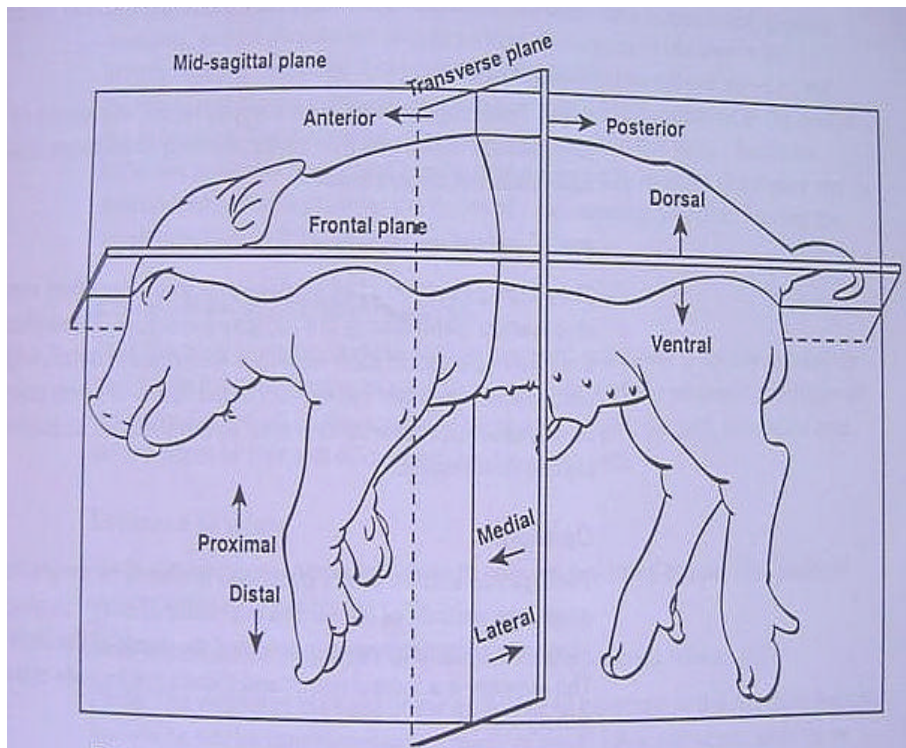


Cadaver Anatomy Terminology:



Cadaver- dead organism.

Anatomy- field of study of the structure of a body; derived from Greek word "anatomē" meaning cutting up.

Dissection- technique used to study anatomy; Latin word for anatomē.

Ventral- towards the belly (front), lower or underside of a body

Dorsal- towards the back (back); upper side of a body

Anterior- head end, the direction toward the head

Posterior- "foot" or "tail" end, the direction toward the tail or rear end

Median or Midsagittal Plane- divides the body into right and left halves.

Sagittal Plane- any plane parallel to the midsagittal plane, divides a body into right and left parts

Coronal or Frontal Plane- vertical plane at right angle to the midsagittal plane; divides body into ventral and dorsal parts.

Transverse Plane- plane at right angles to a vertical plane, divides a body into anterior and posterior parts.

Horizontal Plane- plane parallel to the horizon

Medial- toward the median plane, runs from head to tail

Lateral- away from the median plane, toward the side of a body

Cranial- toward the head

Caudal- away from the head

Distal- signifies a position farther from the point of attachment

Proximal- signifies a position closer to the point of attachment

Inferior- describes a location on a body that is physically lower than something else.

Superior- describes a location on a body that is physically higher than something else.

Longitudinal- Longways

Bilateral Symmetry- similar on two sides